

The Urologic 3 M's

Myths

Misconceptions

Mistakes

Disclosures

- None

The Urologic 3 M's

- Undescended Testes
- Circumcision
- Hydrocele
- Antenatal hydronephrosis
- Urine collection

Undescended testis

Myths

It will come down by age 6

Misconceptions

Ultrasound is necessary

Mistakes

The scrotum looks full

Not examining male genitalia

You have been following a 6 year old boy since birth. Several past notes read “Normal genitalia”. On today’s exam neither testis is in the scrotum but you can feel both in the groin. What do you do?

1. Plan to check again on your next physical exam
2. Order an ultrasound exam
3. Instruct parents to massage the groin to bring them back down
4. Reassure parents that they will eventually come down
5. Refer to Urology

0%



1

0%



2

0%



3

0%



4

0%



5

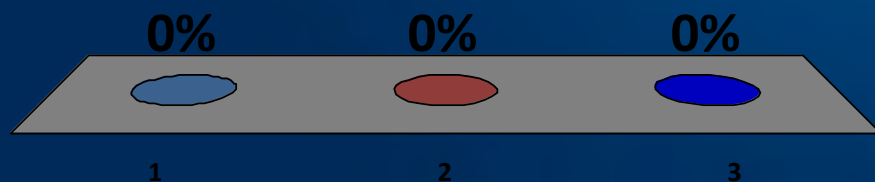
A four year old girl you have followed for vesicoureteral reflux that presumably has resolved, presents with a fever of 103. She is toilet trained but does have day and night wetting. Would you check her urine?

1. Yes
2. No



If yes, how would you obtain a specimen?

1. Clean catch only and culture
2. Catheter only and culture
3. Catheter for culture if clean catch is abnormal on urinalysis

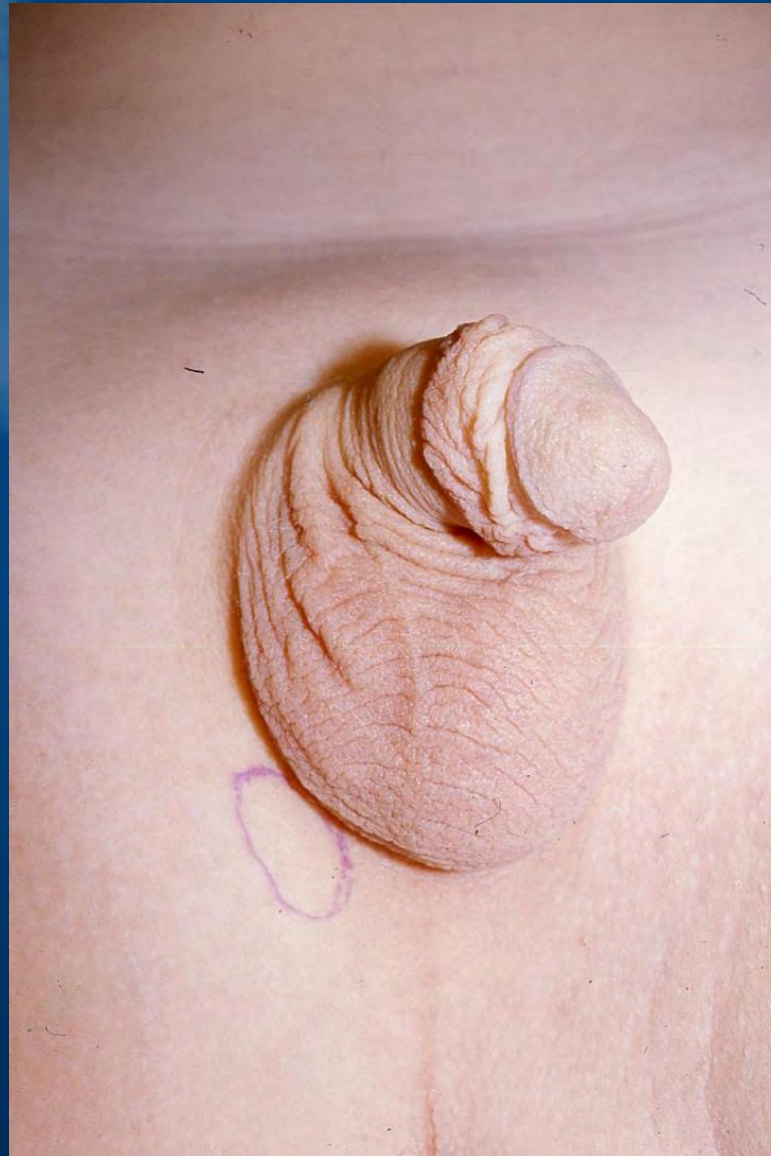

Undescended testis

INCIDENCE UDT

Premature	102-17%	(Av 30 3%)
Term	12-0 7%	(Av. 3 4%)
1 year	0 7-0 8%	
5 year	1 15-2 29%	
8 year	2 40-6 23%	
11 year	4 05-5 47%	
17-37 year	0 7-0 8%	

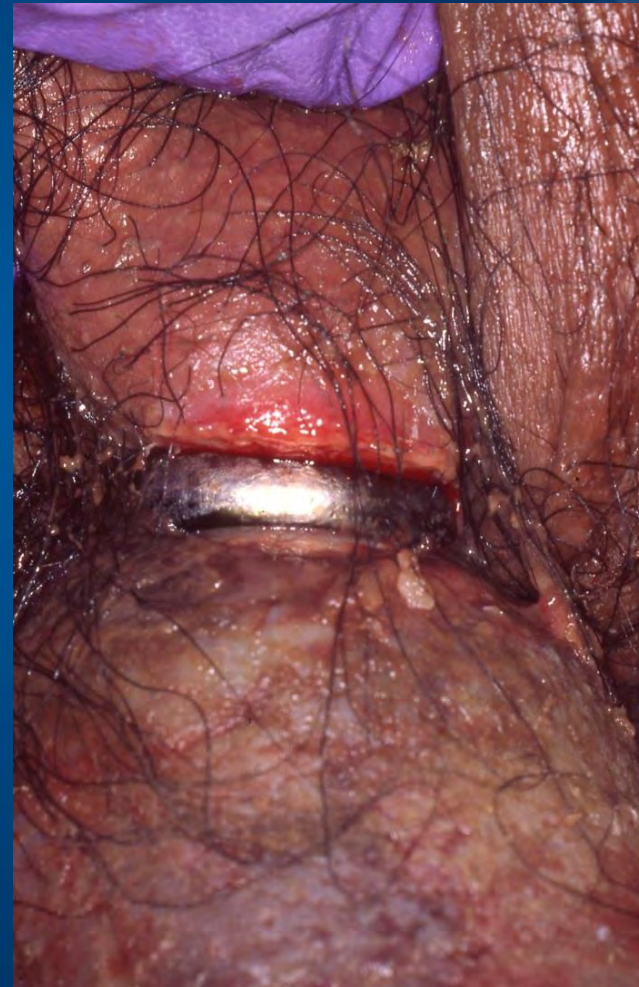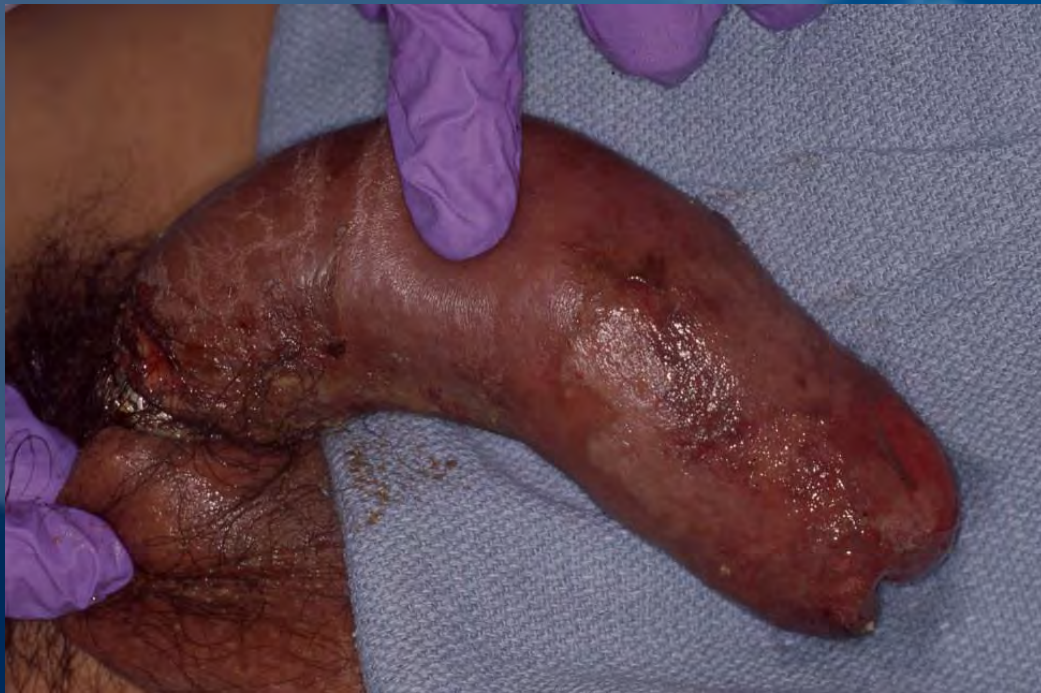Undescended testis



AUA Guidelines

- Evaluation and Treatment of Cryptorchidism
J. Urol. 192:337-345, 2014

Cause of “hip pain” (nobody looked)



Circumcision

Misconceptions

Not understanding the natural history of preputial development

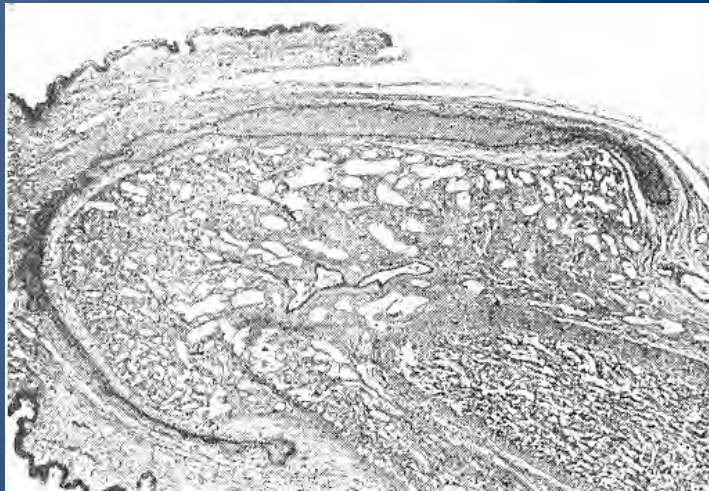
Myths

The foreskin must be retractable by age 5

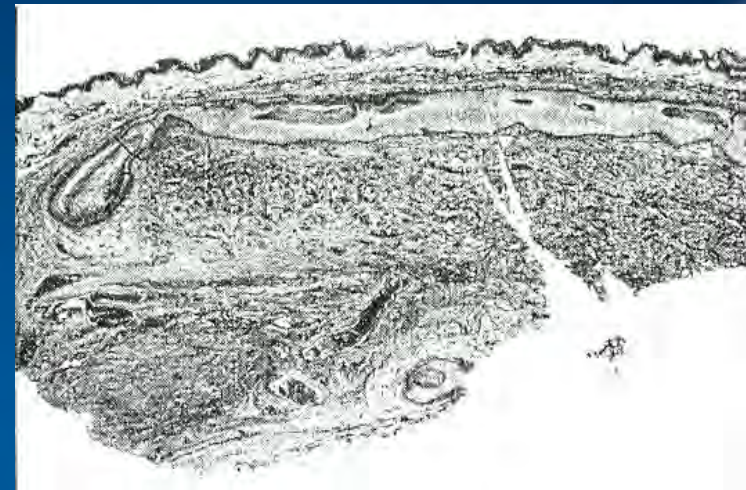
Mistakes

Forcefully retracting the foreskin

Evolution of preputial retractability



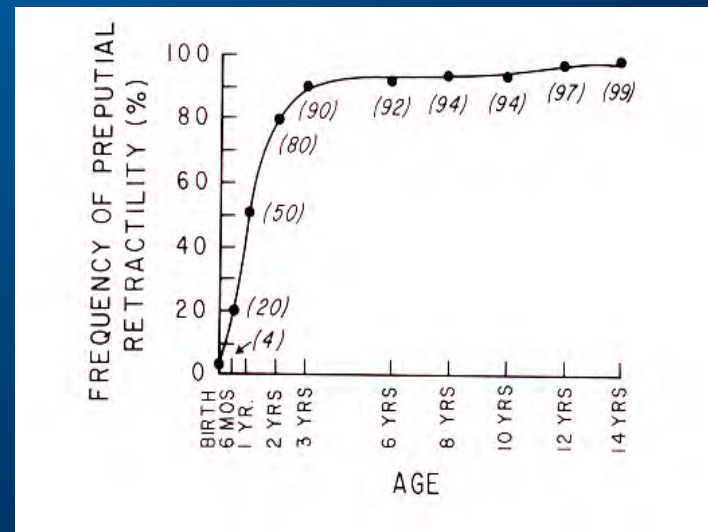
Initially fused



Spaces form



Sulcus free

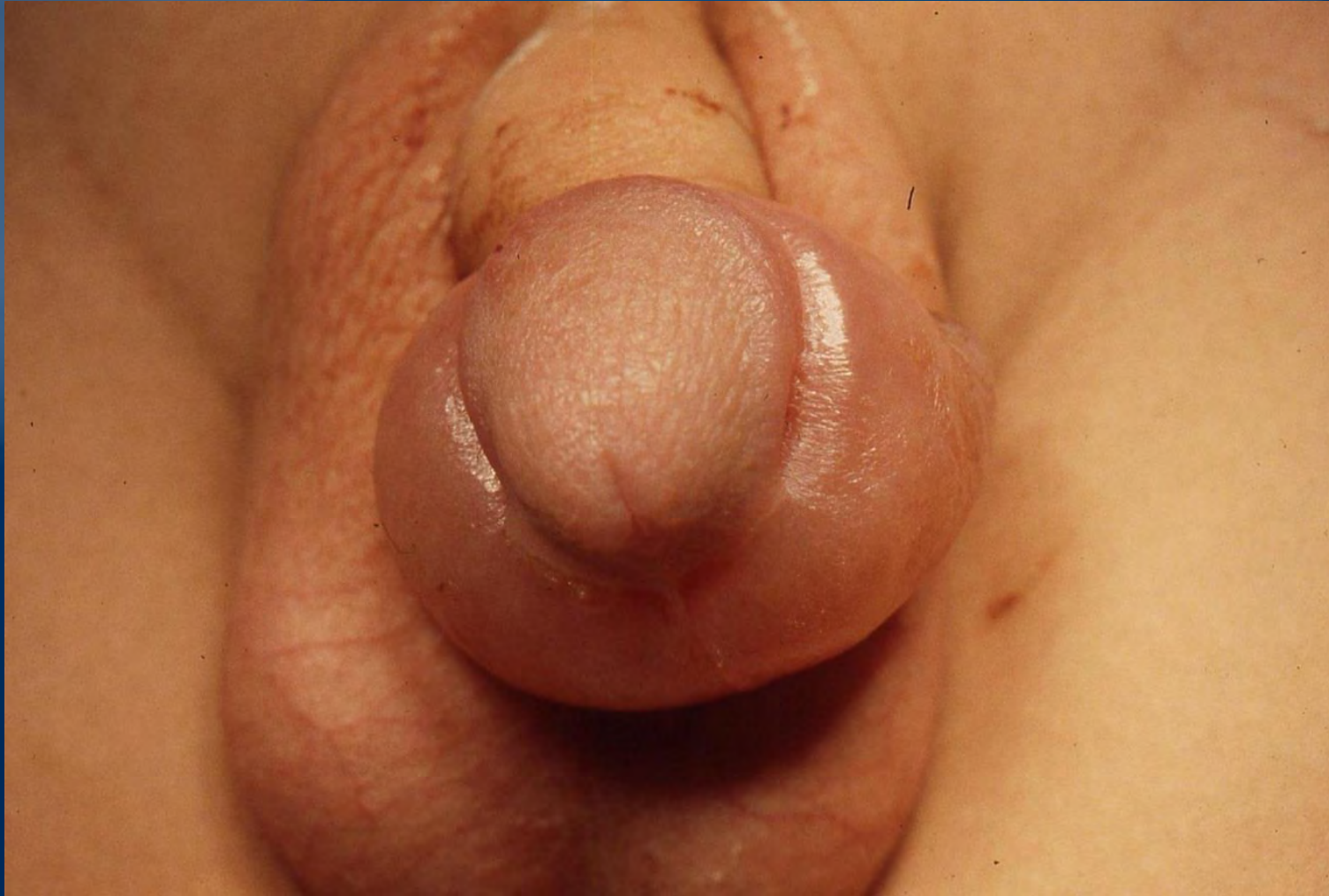

Gardner 1946

PARAPHIMOSIS



PARAPHIMOSIS



Hydrocele

Misconception

A bluish hue to the scrotal wall is abnormal

A large hydrocele must be repaired urgently

Mistakes

Not identifying the testis within the hydrocele

Urine Collection

Myths

The method of collection is unimportant

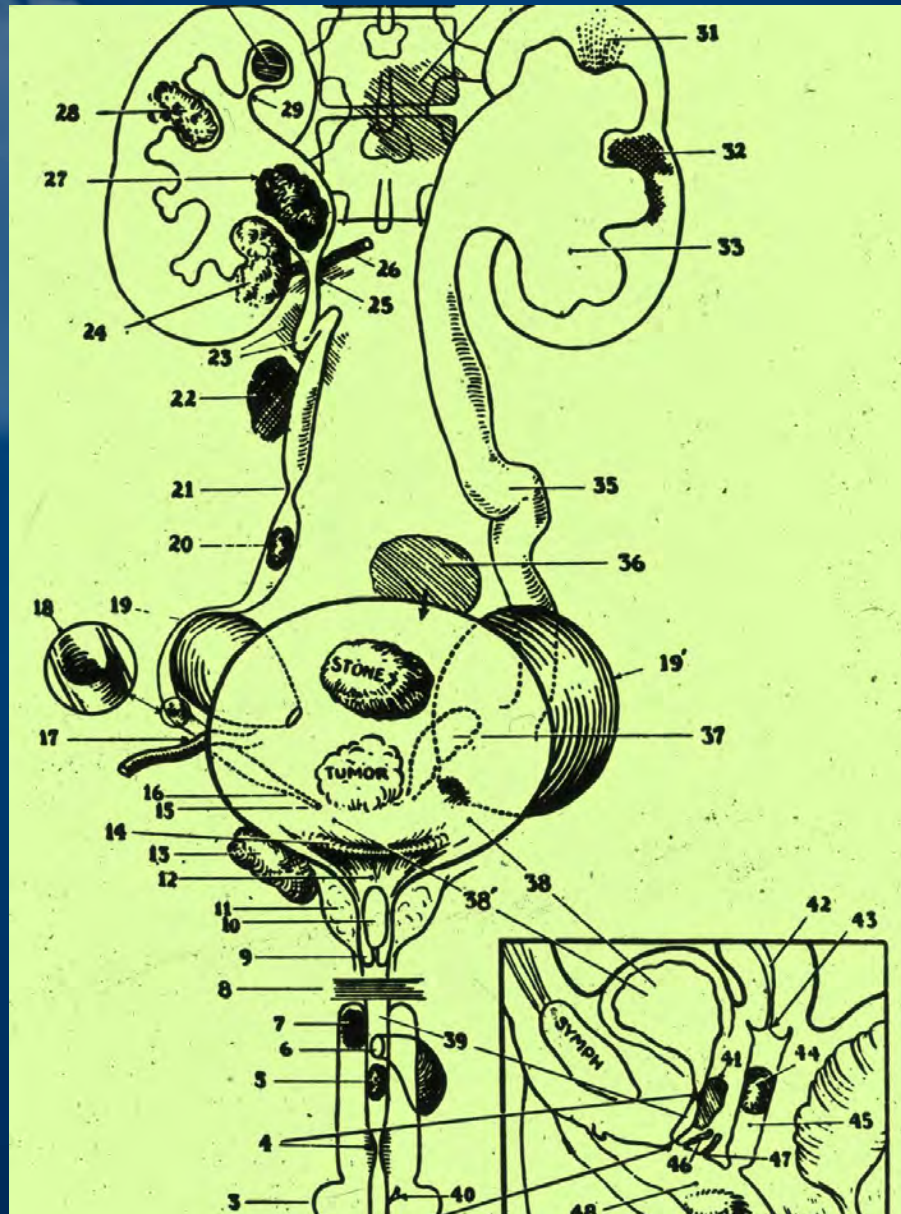
Misconceptions

10^5 colonies is always an infection in a clean catch specimen

Mistakes

Treating a suspected infection on the basis of symptoms or u/a alone


Causes of PYURIA



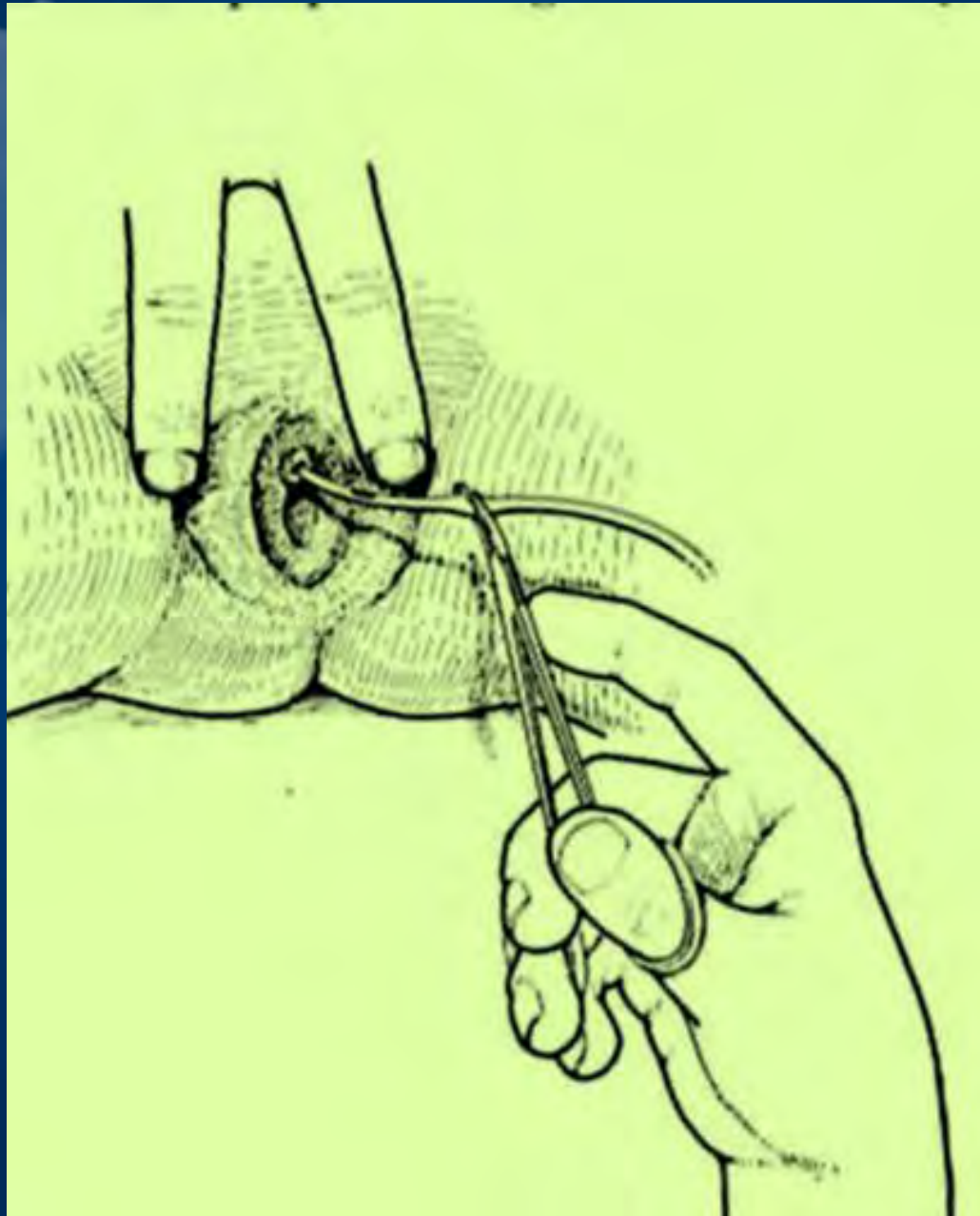
Clean Catch

- Stamey
- Movie

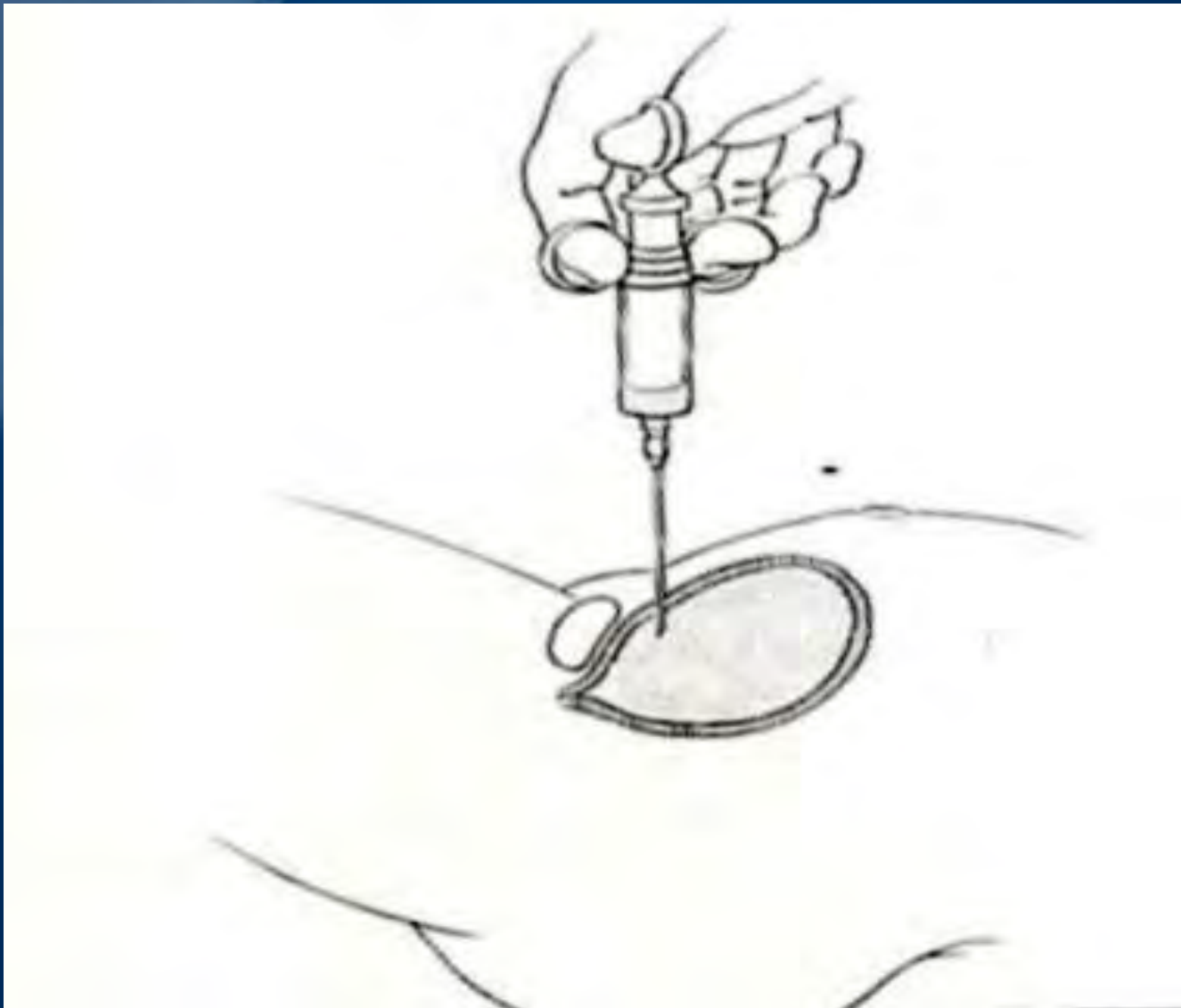
Collection Bags for Infants



Catheterization



Suprapubic aspiration



Why does it matter?

Overdiagnosis of urinary tract infection leads to

Unnecessary antibiotics

Unnecessary studies

Ultrasound

VCUG

Unnecessary surgery in patient with
known urinary tract abnormality

Antenatal Hydronephrosis

Misconceptions

Vesicoureteral reflux is benign and therefore does not need to be pursued

Mistakes

Not following up a maternal history of antenatal hydronephrosis

Competing guidelines

- AUA
Management and
Screening of Primary
Vesicoureteral Reflux in
Children. J Urol. 184
(3): 1134-1144, 2010

- AAP
Urinary Tract
Infection: Clinical Practice
Guideline. Pediatrics
128(3) 596-610, 2011

Thank You!

George Kaplan, MD

858-966-8603

gkaplan@rchsd.org